



# Treatment of Peripheral Nerve Tumors

Julius July<sup>1</sup>, Abhijit Guha<sup>2</sup>

1. Department of Neurosurgery, Medical School of Universitas Pelita Harapan, Siloam Lippo Karawaci Hospital, Tangerang, Indonesia

2. Professor, Department of Surgery; Alan & Susan Hudson Chair in Neurooncology Toronto Western Hospital, University Health Network; Co-Director, Arthur & Sonia Labatts Brain Tumor Centre, Hospital for Sick Children's Research Institute, Univ. of Toronto, Ontario, Canada

## INTRODUCTION

All cellular elements that comprise a peripheral nerve (perineural cells, Schwann cells and fibroblasts) can theoretically give rise to peripheral nerve tumors (PNTs). The tumors are classified as either benign or malignant, and sub-classified according to their origin from either neural or non-neural elements (Table 1).

## HISTORY AND PHYSICAL EXAMINATION

When a soft tissue mass is associated with sensory and/or motor symptoms supplied by a known peripheral nerve, the suspicion of a peripheral nerve tumor is readily apparent. Then a focused history of patient to harbor a peripheral nerve tumor (PNTs) should be directed towards the onset, duration, and growth alterations of the mass. A family history of NF-1 or NF-2 or other predisposition syndromes is of special importance, since majority of PNTs are linked with these syndromes. Presence or absence of symptoms and signs such as pain, numbness, weakness, the overlying skin temperature and color, fluctuance, along with the patients general health inquiry including immune status, pre-existing malignancy are of importance in the differential diagnosis. However, many peripheral nerve tumors present without any neurological symptoms due to their slow growth rate or origin from a superficial small sensory branch. Several features of the examination that suggests a peripheral nerve origin<sup>(1)</sup>: **1.** PNTs are mobile perpendicular but not along the

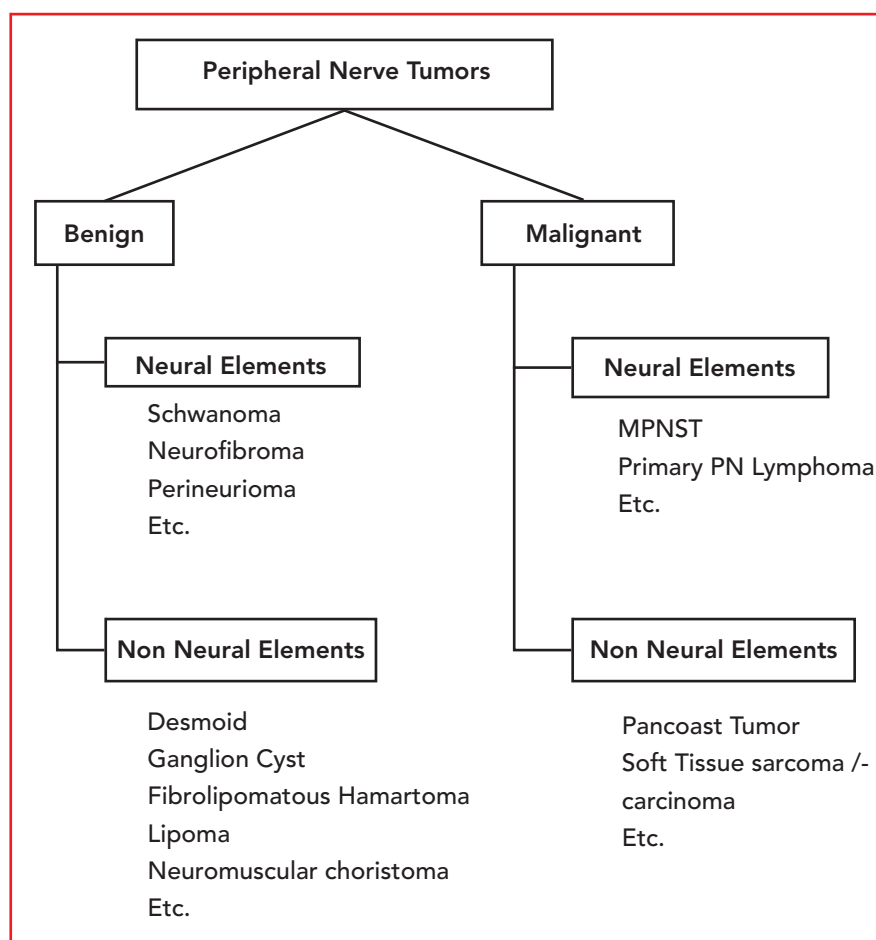


Table 1. Peripheral Nerve Tumors Simple Classification Scheme

longitudinal axis of a known peripheral nerve. **2.** Palpation or percussion (Tinel's sign) of a PNT may elicit sensory stimuli radiating along the distribution of the nerve of origin. **3.** A mass in the presence of a patient with a genetic predisposition such as neurofibromatosis (NF) most likely represents a pe-

ripheral nerve tumor.

## DIAGNOSTICS

Nerve conduction and EMG evaluation are not generally performed in the management of PNTs as they are not diagnostic nor do they help in the management decision. However,



intra-operative electrophysiology is crucial as discussed below. Plain X-ray and CT scans are occasionally helpful, especially to demonstrate remodeling of adjacent bony structures such as the neural foramina. Angiography or MR angiography is rarely required, and restricted to large PNTs at the base of the neck, chest or retroperitoneum, where close proximity and or rarely vascular invasion may be present. MRI is the most useful and sensitive technique, often but not always revealing the nerve of origin (Fig. 1). It is especially useful in determining the relationship of the mass to adjacent anatomical structures, which are of relevance.

Although CT scan or MRI cannot distinguish between the various subtypes of PNTs and determine whether a lesion is benign or malignant (2,3), MR imaging may be highly suggestive but not diagnostic of the sub-type of PNT, with elements of the history and physical examination often superior in predicting whether the lesion is benign vs. malignant and the likely sub-type of PNT to be present. Occasionally, MR imaging of schwannoma demonstrates the nerves of origin, and the displaced passer-by fascicles around the capsule, consistence with its typical extra-fascicular growth. In contrast, neurofibromas are more fusiform (ie. spindle) or multi-nodal, suggestive of their typical intra-fascicular growth. Of note, a PNT in the context of an NF-1 patient will most certainly be a neurofibroma vs. an NF-2 patient who likely harbors a schwannoma. Lipomas have the characteristic bright on T1 and T2 signal, while ganglion cysts are bright on T2 with the origin traced to joint capsule in proximity to the nerve.

MRI of PNTs may demonstrate heterogeneous enhancement, indicating intra-tumor hemorrhage, necrosis or cystic degeneration. However, its relationship to malignancy is poor. In fact, there are no definitive radiological features of a Malignant Peripheral Nerve Sheath Tumor (MPNST), a diagnosis mainly suspected on rapid

clinical and radiological growth, progressive neurological deterioration and most importantly pain. Use of <sup>18</sup>F-FDG PET scanning, a developing technique for dynamic imaging of glucose metabolism(4,5), is of potential promise in distinguishing MPNST from benign PNTs. Still, one should be aware of the occasional false-negative

results with this modality(6). Initial studies have shown that <sup>18</sup>F-FDG-PET can be used to identify potentially malignant transformation of a benign plexiform neurofibroma to a MPNST. In those instances where malignant transformation is probable but not yet confirmed, biopsy of the lesion before surgery is essential.

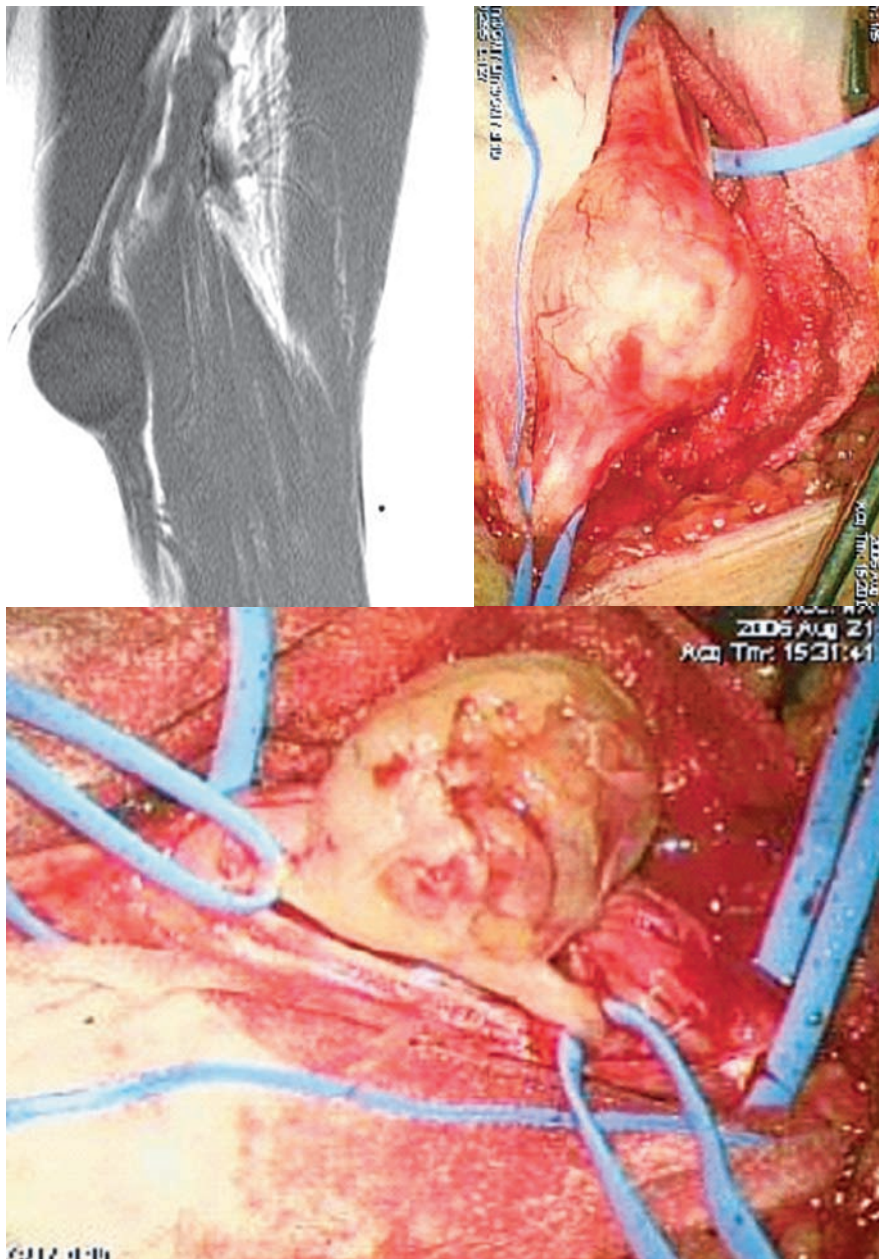


Figure 1. Patient with Left median nerve schwannoma. Upper Left: T1W MRI showed a masses along the course of left median nerve with obvious nerve origin. Upper Right: intraoperative picture showed proximal and distal part before dissection to identify the nerve and isolated with rubber band. Lower: Identifying the nerve and isolated with rubber band. Schwannoma always can be separated from the nerve and leave the nerve intact.



### OPERATIVE PRINCIPLES

There are several operative principles that are applicable for all peripheral nerve tumors<sup>(1)</sup>, such as:

- 1) Anesthetic without neuromuscular paralysis to allow intra-operative nerve stimulation.
- 2) The limb was positioned and draped to allow anatomical accessibility and evaluation of the distal muscles that are supplied by the nerve of origin.
- 3) The incision over the tumor should extend proximally and distally to allow adequate exposure of the nerve of origin at either pole of the tumor, coursing in a curvilinear fashion over flexor/extensor creases. If the tumor is adjacent to a known entrapment point such as the carpal tunnel or fibular head at the knee, the incision should allow prophylactic release of the entrapment point in conjunction with tumor removal.
- 4) Magnification, intraoperative electrophysiological monitoring including Nerve Action Potentials

(NAP), and microneurosurgical instruments should be ensured. Ultrasonic aspiration is sometimes required to internally debulk large PNTs, which allows the tumor capsule to be collapsed and facilitating subsequent dissection of the passerby fascicles from the tumor capsule.

- 5) The first step of dissection involves isolating of the proximal and distal segments of the nerve of origin from adjacent vascular and soft tissue structures and encircling them in vessel loops.
- 6) Gross observation of the tumor and the position of the displaced fascicles will often reveal the underlying pathology and vital to avoid injuring the nerve during tumor removal<sup>(7,8,9)</sup>. In schwannomas, passerby fascicles will be found displaced relative to the tumor capsule, though they may be quite attenuated. The routes of these fascicles should be noted microscopically and evaluated with electrical stimulation noting distal muscle activity. Neurofibromas

in contrast typically do not reveal the discrete passerby fascicles, as nerve fascicles are encompassed within the tumor. However, several major fascicles may be displaced around the bulk of the tumor and their position in the tumor capsule should be noted.

- 7) A small biopsy of the tumor from an electrically silent region is sent for pathological verification. The pathology in conjunction with the gross and microscopic observation will determine the feasibility of total removal (as in schwannomas) vs. limited resection (as in neurofibromas, desmoids). If the quick section pathology suggests a neurogenic sarcoma, then we recommend closure and management as outlined below.

Using the principles outlined above, the single nerve fascicle which gives rise to the schwannoma can usually be isolated and electrophysiologically confirmed to be non-conducting, and then total removal of the tumor can be undertaken, (Fig 1).

### REFERENCES:

1. July J, Guha A. Surgical Management of benign peripheral nerve tumors. *Medical Journal of Indonesia* 2008;17(3): 163-8.
2. Levine E, Huntrakoon M, Wetzel L. Malignant-nerve sheath neoplasms in Neurofibromatosis: Distinctions from benign tumors by using imaging techniques. *Am. J. Radiol.* 1987;149:1059-1064.
3. Suh J, Abenzoza P, Galloway H, Everson L, Griffiths H. Peripheral (extracranial) nerve tumors: Correlation of MR imaging and histological findings. *Radiology* 1992;183:341-346.
4. Adler LP, Blair HF, Makley JT, Williams RP, Joyce MJ, Leisure G, Al-Kaisi N, Miraldi F. Noninvasive grading of musculoskeletal tumors using PET. *J Nucl Med.* 1991;32:1508-12.
5. Lucas JD, O'Doherty MJ, Wong JCH, Bingham JB, McKee PH, Fletcher CDM, Smith MA. Evaluation of fluorodeoxyglucose positron emission tomography in the management of soft tissue sarcomas. *J Bone Joint Surg (Br)* 1998;80-B:441-7.
6. Hsu CH, Lee CM, Wang FC, Fang CL. Neurofibroma with increased uptake of (F-18)-fluoro-2- deoxy-D-Glucose interpreted as a metastatic lesion. *Ann Nucl Med* 2003;17:609-611.
7. Hudson A, Gentili F, Kline D. Peripheral Nerve Tumors. In: Schmidek H, Sweet W (Eds). *Operative Neurosurgical Techniques*. Grune & Stratton, New York 1988. pp. 1599-1610.
8. Kline D, Hudson A. *Operative Results of Major Nerve Injuries, Entrapments and Tumors*. W. B. Saunders, Philadelphia. 1994.
9. Rosenberg A, Dick H, Botte M. Nerve Tumors. In Gilberman R (Ed.), *Operative Nerve Repair and Reconstruction*, J.B. Lippincott, Philadelphia, 1991.